
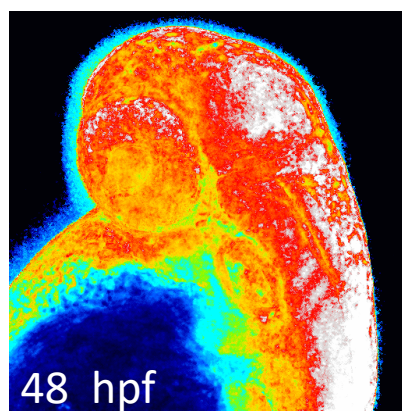


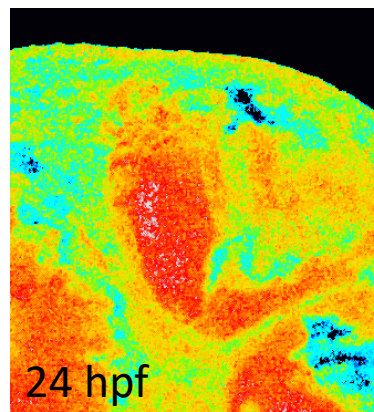
Neural tube



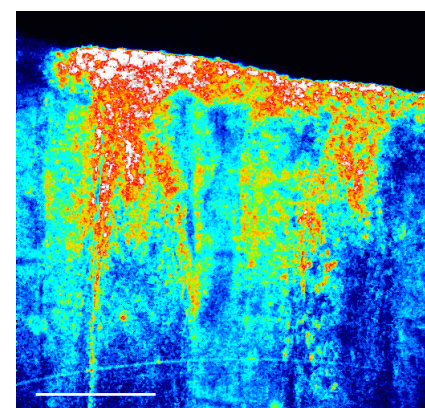
Optic tectum




MHB boundary



Adult caudal fin (16 hpa)

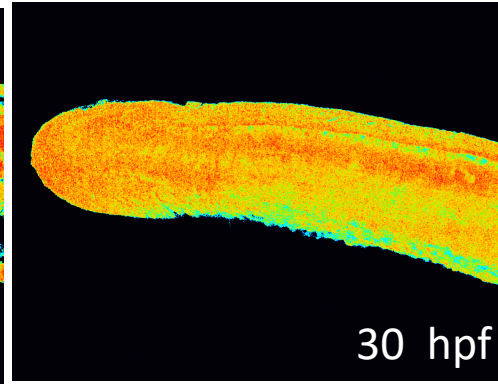
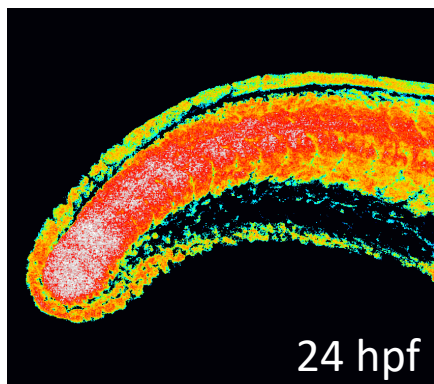

[H₂O₂]
high

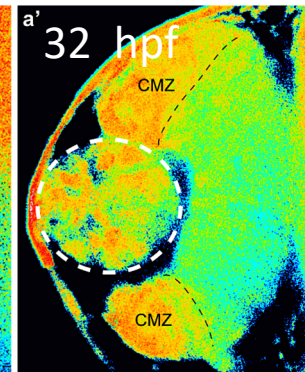
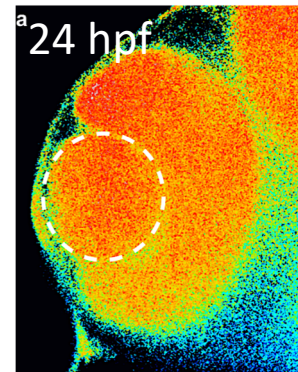


[H₂O₂]
low

Caudal bud



Retina



Heart

